

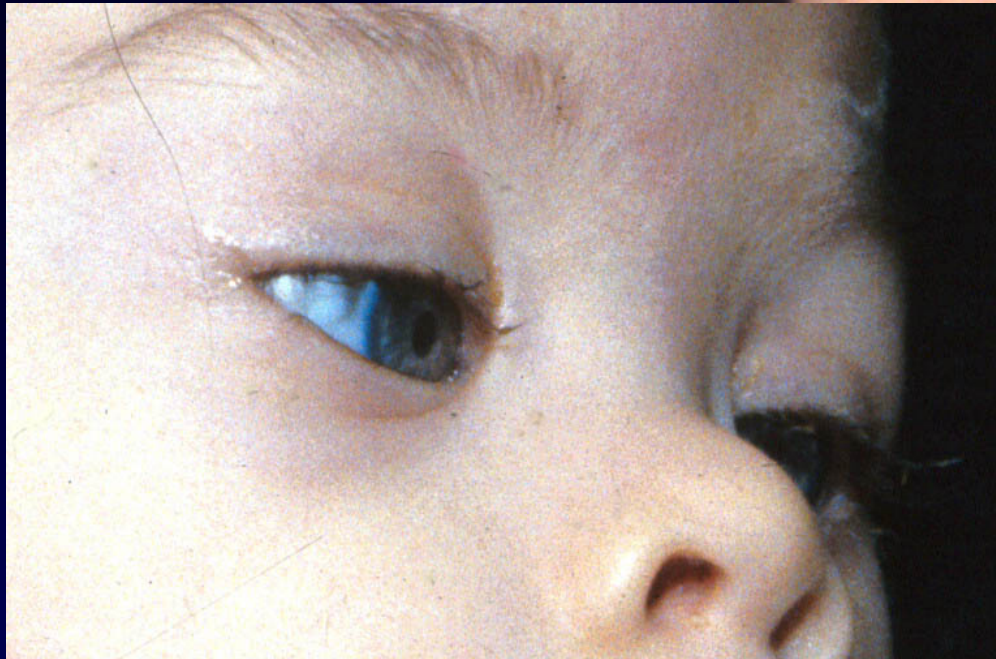
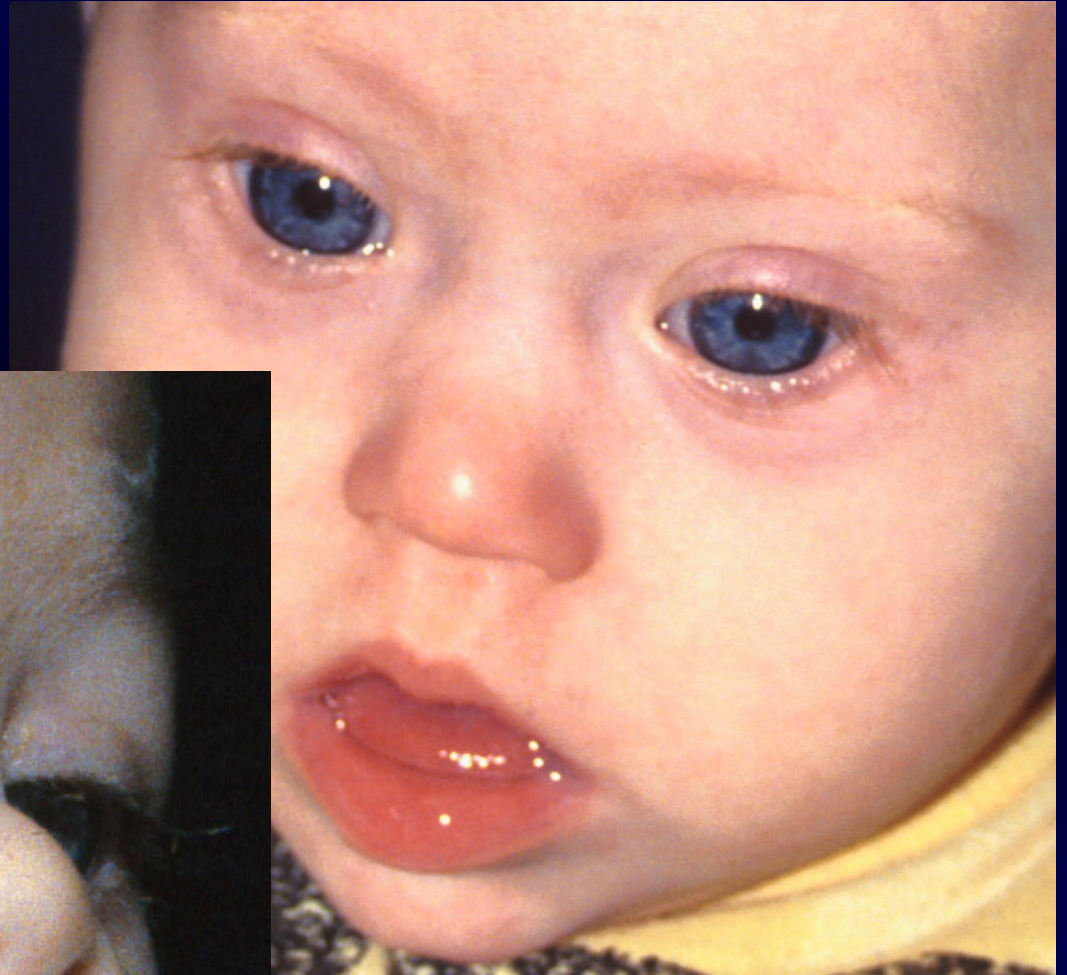
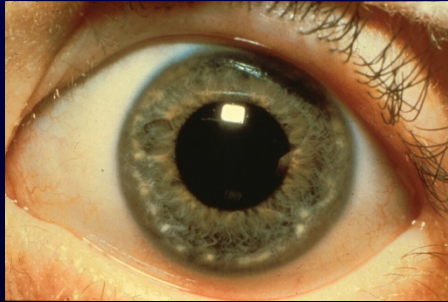
Trisomy 21: Down Syndrome

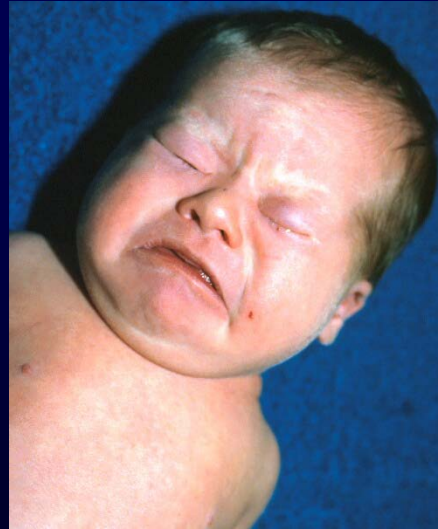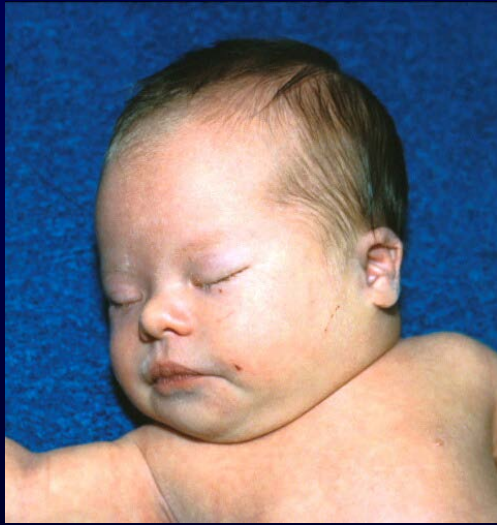- Muscular hypotonia
- Flattened occiput
- Up-slanting palpebral fissures
- Protruding tongue
- Small ears, full back of neck
- Congenital heart disease
- Short fingers, single palm creases

Trisomy 21

- Advanced maternal age
- Types
 - 94%: full trisomy, nondisjunction
 - 3%: mosaic trisomy
 - 4%: translocation
- Precise reason for the chromosome nondisjunction event is unknown

Brushfield Spots





Hypotonia
Epicanthal folds
Single transverse palm crease
Superior axis on ECG

