The Ehlers-Danlos Syndromes

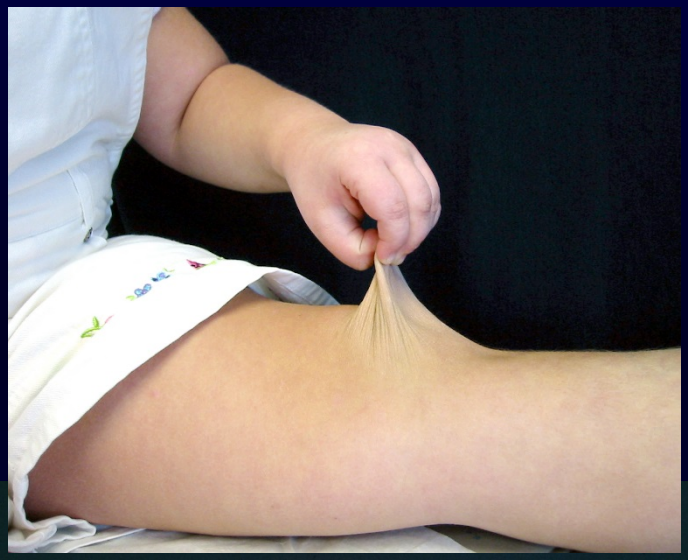

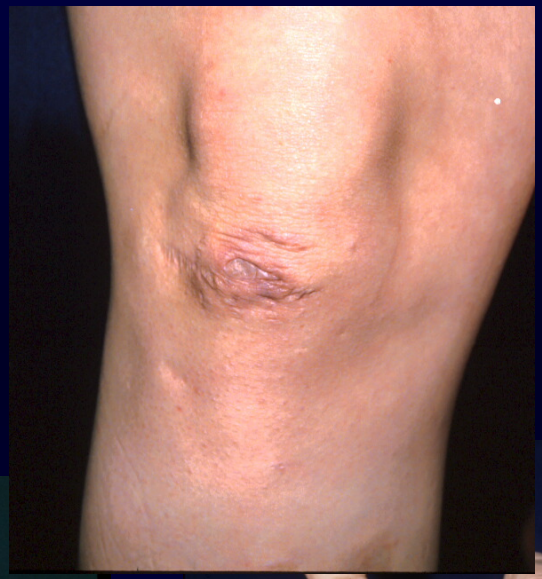

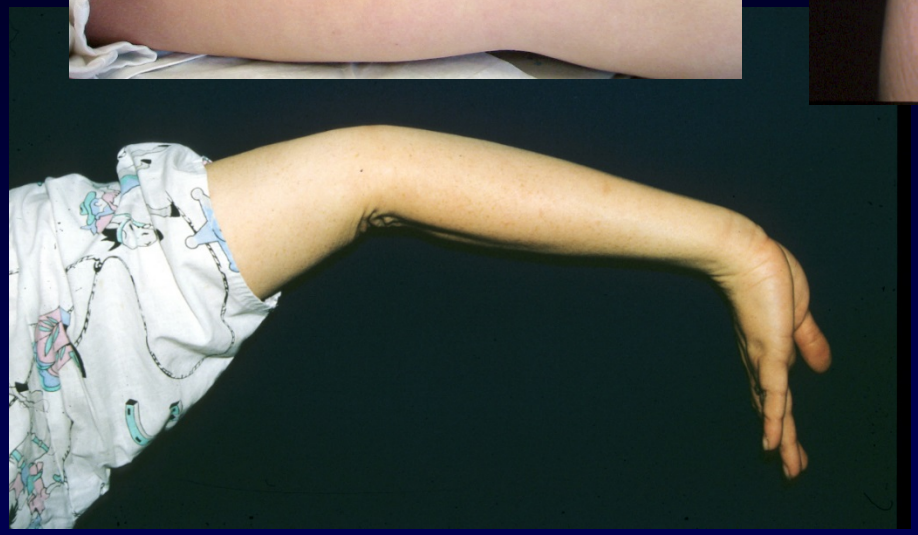

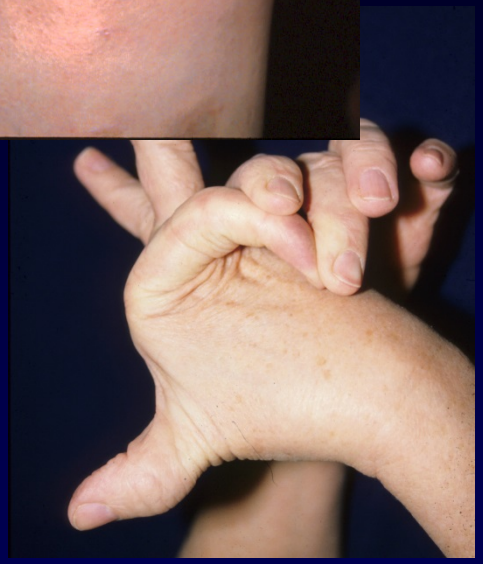

Ehlers-Danlos Clinical Variations!

Types of Ehlers-Danlos syndrome		
Villefranche types	Corresponding Berlin types	Collagen defects
Classical	I (gravis) II (mitis)	Type V
Hypermobility	III (hypermobile)	Unknown
Vascular	IV (arterial-ecchymotic)	Type III
Kyphoscoliosis	VI (ocular-scoliotic-MR)	Lysyl hydroxylase
Arthrochalasia	VIIa; VIIb (arthrochalasis multiplex congenita types)	Type I
Dermatosparaxis	VIIc (human dermatosparaxis)	Procollagen N-peptidase
Not classified	V, VIII, IX, X, XI	Unknown

2007

EDS: Classical Type

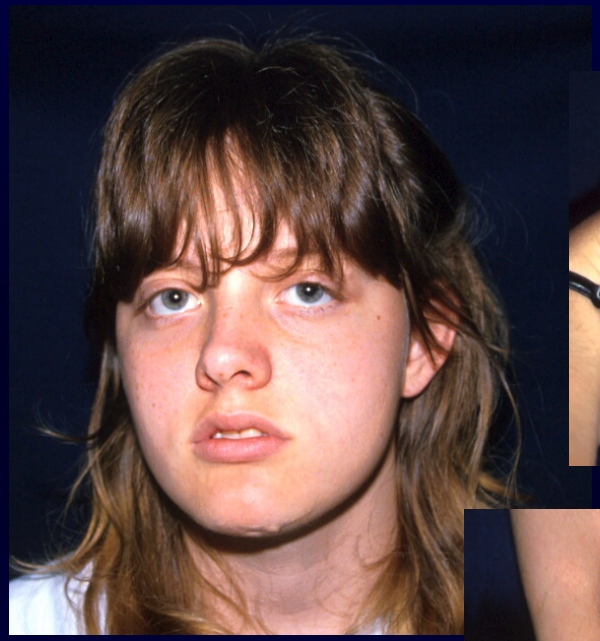

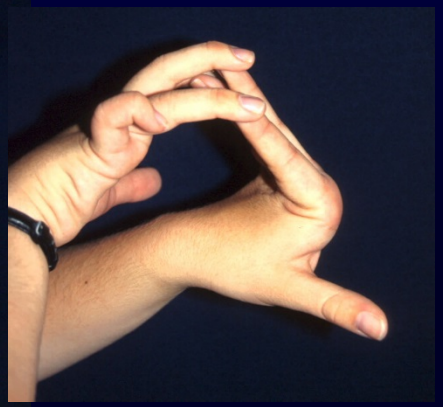

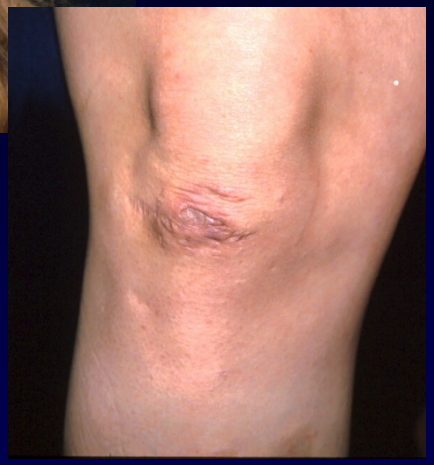

- AD: COL5A1, COL5A2
- Skin hyperextensibility
- Wide atrophic scarring
- Joint hypermobility
- Traumatic bruising
- Bleeding tendency
- Mitral or tricuspid valve prolapse
- Joint subluxations

EDS: Hypermobility Type

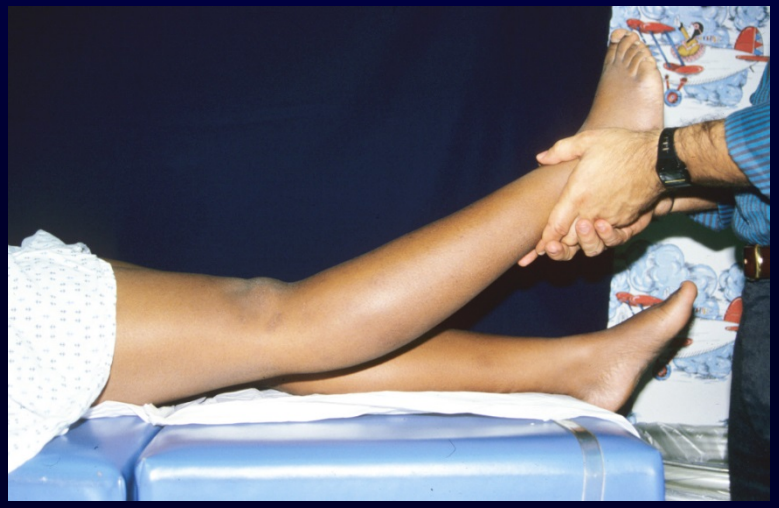

- AD: unknown gene
- Generalized joint hypermobility is dominant feature
- Mitral valve prolapse
- Variable skin hyperextensibility
- Some events of shoulder or knee dislocation
- For diagnostic scoring sheet: https://www.ehlers-danlos.com/heds-diagnostic-checklist/

EDS: Vascular Type

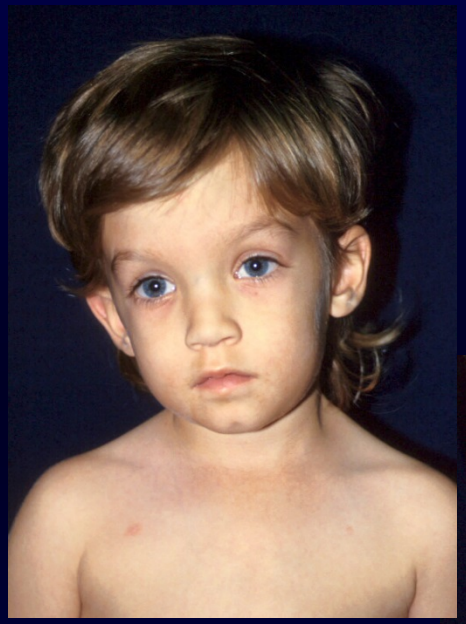

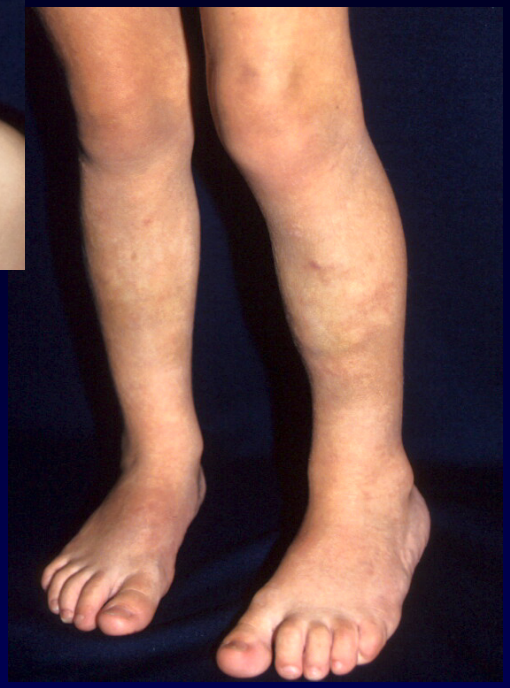

- AD: COL3A1
- Easy and excessive bruising
- Smooth muscle wall fragility
- Small joint hyperextensibility
- Translucent, thin skin
- Arterial rupture
- Inguinal hernia
- Pneumothorax
- Early death

EDS: Kyphoscoliosis type

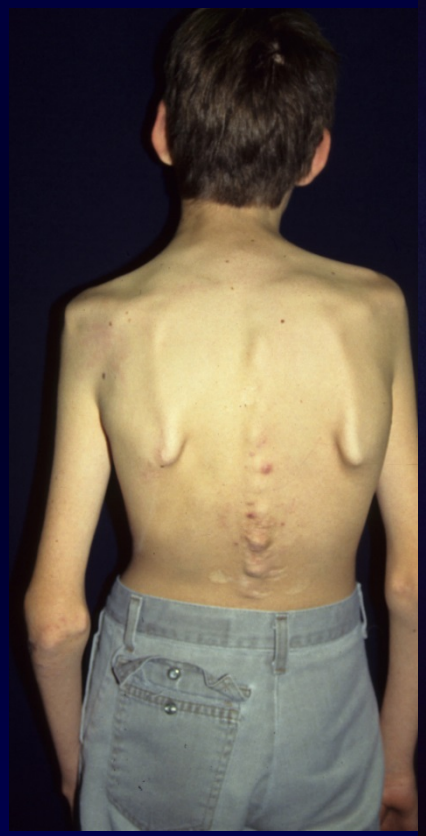

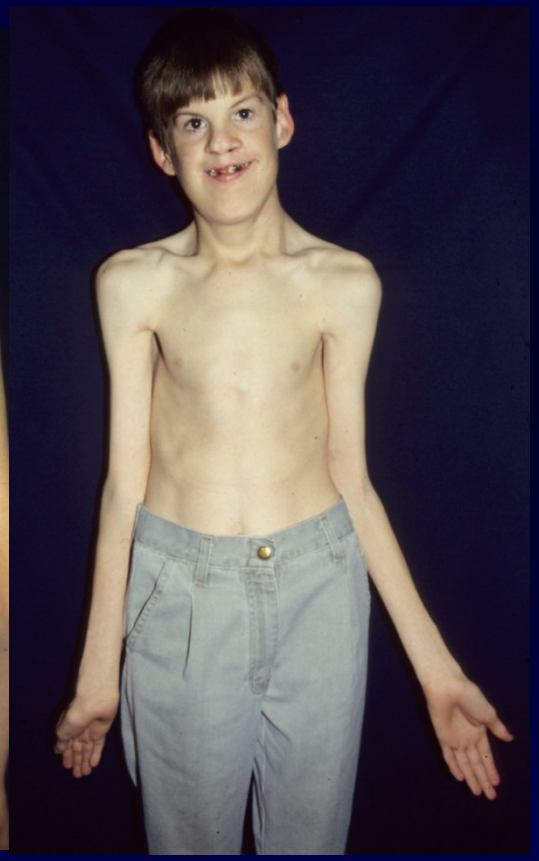

- AR: PLOD (lysyl hydroxylase)
- Congenital scoliosis
- Hypotonia
- Mental retardation
- Ocular globe rupture
- Severe skin scarring

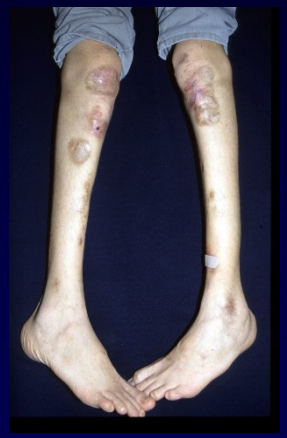

EDS: Arthrochalasia type

Giunta C, et al., J Bone Joint Surg Am, 1999

- AD: exon 6, COL1A1, COL1A2
- Severe generalized joint hypermobility
- Recurrent subluxations, large and small joints
- Mild scoliosis
- Ecchymoses
- Kyphoscoliosis
- Osteopenia
- Congenital bilateral hip dislocation

EDS: Dermatosparaxis type

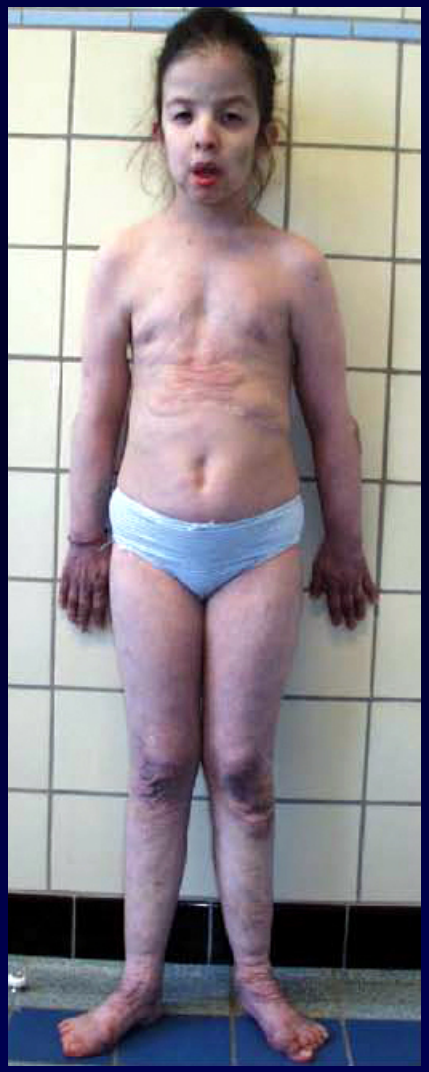

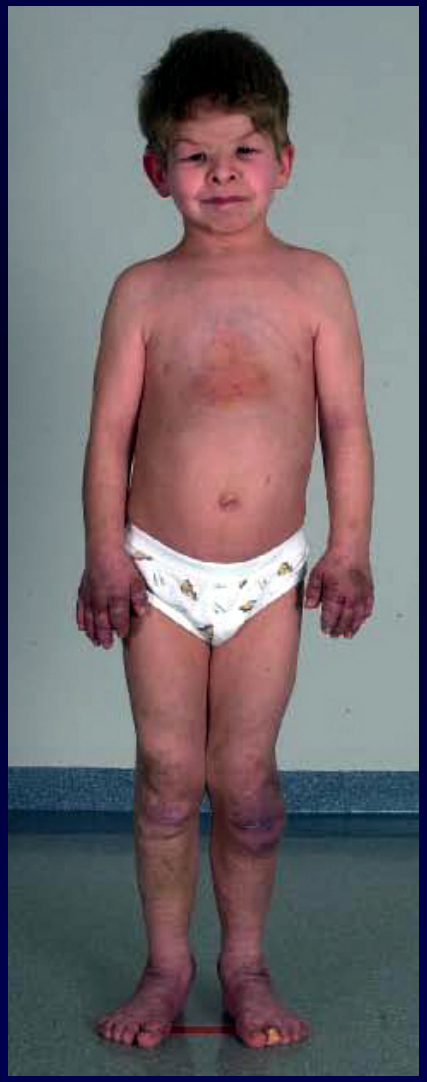

Malfait F, et al., Am J Med Genet A, 2004

- AR, ADAMTS2, procollagen N-peptidase
- Severe skin fragility
- Skin sagging, redundant skin
- Umbilical, inguinal hernias
- Short stature
- Characteristic faces

Diagnostic/genetic approach